



A rare clinical presentation of human *Dirofilaria repens* infection as a pseudo-tumour of the epididymis – Case Report

Vincent Nagy^{1,A-F}, Dana Nagyová^{2,B}

¹ P.J.Šafárik University, Medical Faculty and L.Pasteur University Hospital, Košice, Slovak Republik

² Pallas Klinik, Zürich, Switzerland

A – Research concept and design, B – Collection and/or assembly of data, C – Data analysis and interpretation, D – Writing the article, E – Critical revision of the article, F – Final approval of article

Nagy V, Nagyová D. A rare clinical presentation of human *Dirofilaria repens* infection as a pseudo-tumor of the epididymis – Case report. Ann Agric Environ Med. 2021; 28(2): 348–351. doi: 10.26444/aaem/136387

Abstract

Introduction. Epididymal dirofilariasis is one of the unusual manifestations of this zoonosis. In Slovakia, this is the third case out of 20 *Dirofilaria repens* infected patients in whom the worm (the parasite) was identified in the epididymis. The patient felt a painless tumour about 2 cm in size on the left testicle. During ultrasound examination, the radiologist observed a cyst containing a live worm within the epididymis. After mechanical stimulation, the movement characteristic for filarial worms ('filarial dance sign') appeared. An orchiectomy was performed at the Department of Urology in the University Hospital in Košice. Histopathology confirmed a parasitic cyst with a worm, and based on characteristic morphological features, the parasite was identified as *Dirofilaria repens*.

Objective. The aim of case report is to alert physicians to the possibility dirofilarial infection of the epididymis, where tumors and cystic structures often occur and to present clinical signs of the disease.

Key words

testicular tumor, parasites, *Dirofilaria repens*, Worms, Parasitic Cyst, epididymal filariasis

INTRODUCTION

In 1992, an 18-year-old patient living in north-eastern Slovakia experienced the first documented case of human dirofilariasis in the vitreous of the eye [1], and by the end of 2019, the number of patients with this zoonosis in Slovakia increased to 20 (12 subcutaneous forms, 4 ocular, 1 pulmonary and 3 in the epididymis) [2, 3, 4] – including the original patient. Dirofilariasis in dogs and humans occurs in Slovakia mainly in the endemic south-western region around Bratislava, although isolated cases have also occurred around Stará Ľubovňa, Humenné and Michalovce in the north-eastern part of Slovakia [5].

OBJECTIVE

The aim of this case report is to present a third patient with *Dirofilaria repens* infection in an epididymal cyst, and to describe the clinical, laboratory, ultrasound and histological signs of the disease.

CASE REPORT

A 73-year-old patient, a dentist, visited a urologist after feeling a hard nodule in the caput epididymis area of his left testicle at the end of November 2019. Initially, it was a painless formation about 2 cm in size, without an inflammatory

reaction of the skin. The medical history showed that the patient had been treated in the past for chronic lymphocytic leukemia in remission (CLL) and herpes zoster. He did not disclose close contact with animals and did not observe tick bites or parasites in the stool. The previous year, he had visited a seaside recreation area of Turkey; he does not remember mosquito bites.

At the beginning of December 2019, after the initial urological examination, he underwent a scrotal ultrasound (USG) examination. On USG, a cystic lesion containing worm-like motile tubular structures was found in the caput epididymis area. Detailed USG examination with a 12 MHz ultrasound probe confirmed the presence of a coiled tubular worm in an epididymal cyst (Fig. 1) and the movement of the worm after its mechanical stimulation ('filarial dance sign').

In the cavum serosum scroti, the fluid content increased to a thickness of 15 mm with floating hyperechoic structures. Both testes and epididymis were of normal size and structure, with adequate blood perfusion on USG colour Doppler. Based on the above symptoms, the radiologist assumed a parasitic infection – filariasis.

Standard blood preoperative tests performed prior to cardiopulmonary status assessment were within reference ranges. Serological examination was focused on several parasites, namely *Echinococcus* spp. (Novagnost[®] *Echinococcus* IgG, Siemens Healthcare Diagnostics, Germany), *Taenia solium* (NovaLisa *Taenia solium* IgG, NovaTec Immunodiagnostica GmbH, Germany), *Trichinella spiralis* (NovaLisa *Trichinella spiralis* IgG, NovaTec Immunodiagnostica GmbH, Germany), *Entamoeba histolytica* (NovaLisa *Entamoeba histolytica* IgG, NovaTec Immunodiagnostica GmbH, Germany), *Toxoplasma gondii* (Atellica[®] IM *Toxoplasma* IgM Assay (Toxo M), Siemens

Address for correspondence: Vincent Nagy, P.J.Šafárik University, Medical Faculty and L.Pasteur University Hospital, Tried SNP 1, 040 11, Košice, Slovak Republik
E-mail: vincent.nagy@upjs.sk

Received: 13.10.2020; accepted: 01.04.2021; first published: 06.05.2021

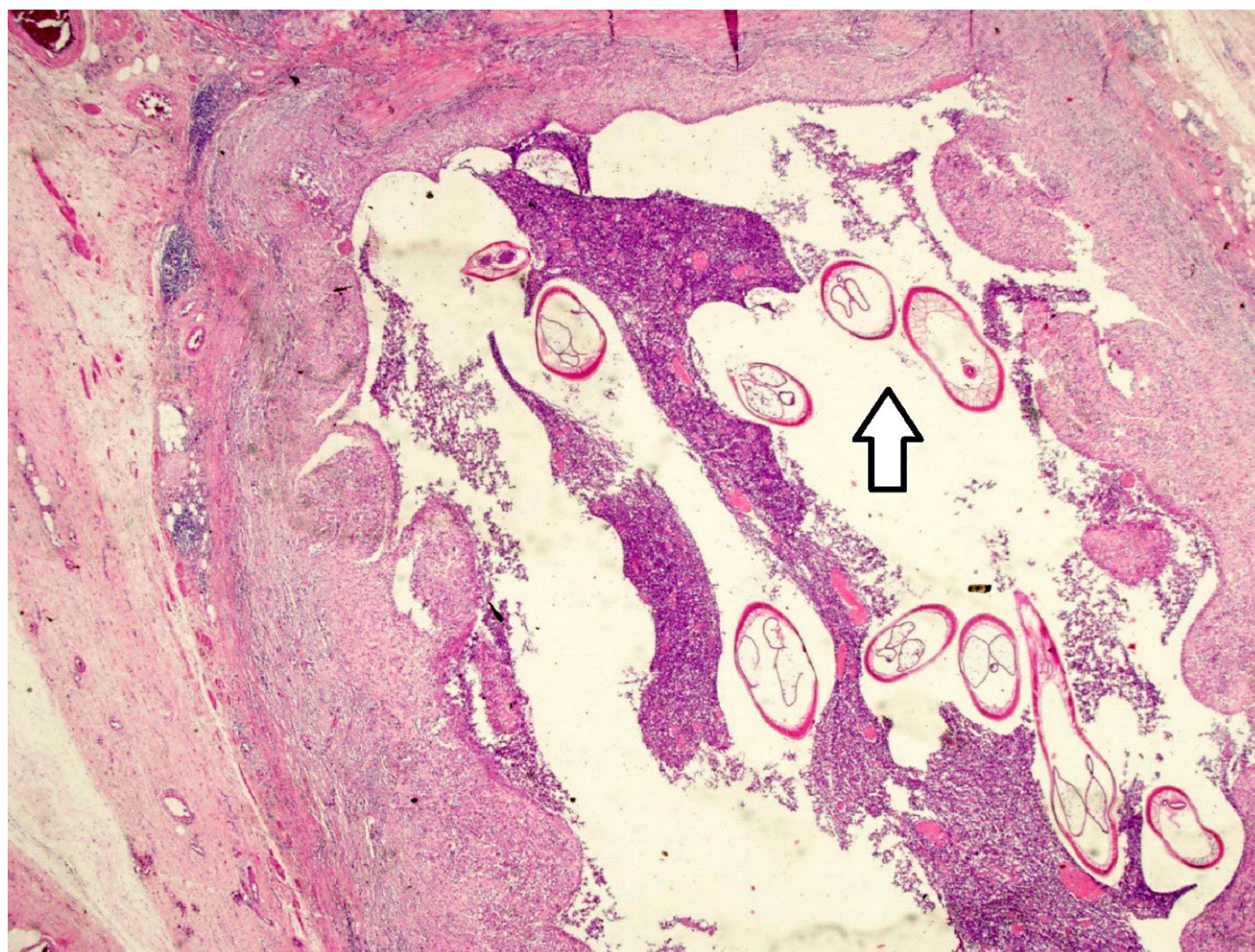


Figure 1. Parasitic cyst with many cross-sections of one coiled worm at low magnification (20x). On histopathological examination, several sections of the worm may resemble parasite eggs (white arrow)

Healthcare Diagnostics, Germany) and *Toxocara* spp. (EIA *Toxocara* IgG, TestLine, Czech Republic). All the above-mentioned serological tests were negative.

Microscopic examination of fresh stool did not confirm the presence of eggs or developmental stages of intestinal parasites.

The infectious disease specialist, at a time when the exact diagnosis was initially unknown, recommended oral treatment with albendazole for 14 days and later, after a 10 day break, continuation of the treatment for a further 7 days at a dose of 2×400 mg per day. The patient was then referred to the urology department. The surgeon suggested extirpation of the lesion or orchiectomy. The patient agreed to orchiectomy after being informed of the nature of his disease. In January 2020, an orchiectomy of the left testicle was performed at the Department of Urology of the University Hospital in Košice. The postoperative course was without complications; the patient currently has no subjective or objective difficulties.

Histopathological examination confirmed a parasitic cyst in the area of the caput epididymis with a size of 25 mm containing an unidentified parasite. The structures of the testis, epididymis and spermatic funnel were without any other significant histological findings. During subsequent consultation at the Institute of Parasitology of the Slovak Academy of Sciences in Košice, the parasite *Dirofilaria repens*

was identified according to morphological features, namely typical external cuticular ridges and internal body organs and structures (Fig. 2–3).

DISCUSSION

By the end of 2019, 20 people have been registered in Slovakia with the infection caused by *Dirofilaria repens* [4]. Currently, dirofilariasis in humans is considered a zoonosis with an increasing incidence in most Central European countries. In humans, it is mainly the transmission of *Dirofilaria repens* most likely occurs after a mosquito bite and the transmission of the parasite into the recipient's blood from an infected dog. During a blood meal, an infected mosquito (*Aedes*, *Anopheles*, *Culex*, *Mansonia*) introduces third-stage filarial larvae of *Dirofilaria repens* into the skin of the canine definitive host (but also occasionally humans), where they penetrate into the bite wound. In humans, the parasite does not usually reach the adult stage and remains confined to an immature form. In the definitive host, the third-stage filarial larvae undergo two more moults into fourth-stage filarial larvae, and adults, the latter of which resides in subcutaneous tissues. Adult female worms are usually 100–170 mm long by 460–650 μ m wide; males are usually 50–70 mm long by 370–450 μ m wide. Adults can live for 5–10 years. In subcutaneous tissue,

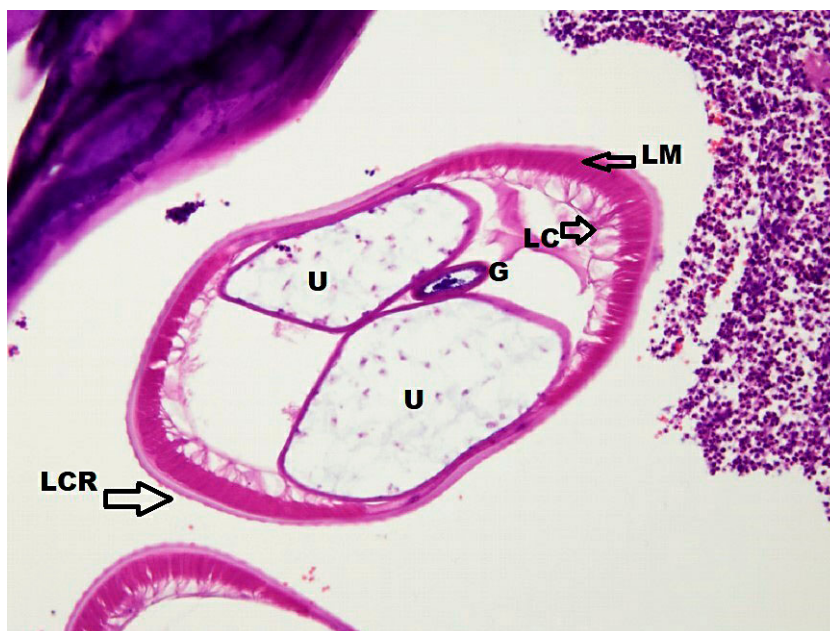


Figure 2. A detailed microscopic examination of the parasite reveals typical structures. Cross-section of the worm showing typical external longitudinal cuticular ridges (LCR), double uterus (U), one central gut section (G), longitudinal muscles (LM) and lateral chords (LC) (HE, x 200)

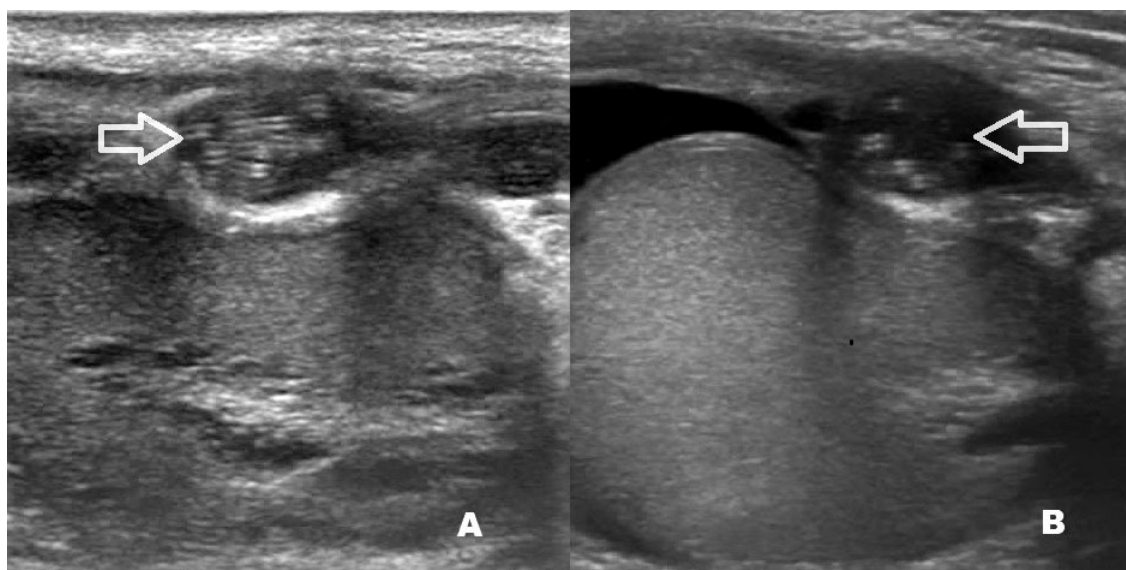


Figure 3. During USG examination with a 12 MHz linear ultrasound probe in the area of the epididymis, a coiled worm (A, B) is observed, marked with an arrow

the female worms are capable of producing microfilariae over their lifespan, which are found in peripheral blood. A mosquito ingests the microfilariae during a blood meal. After ingestion, the microfilariae migrate from the mosquito's midgut through the haemocoel to the Malpighian tubules in the abdomen. There, the microfilariae develop into first-stage larvae and subsequently into third-stage infective larvae which migrate to the mosquito's proboscis, and can infect another definitive host when it takes a blood meal.

In humans, *Dirofilaria repens* usually manifests as either a wandering worm in the subcutaneous tissue or a granulomatous nodule. The worm often reaches the ocular region and occasionally other organs, such as the lungs and epididymis [6].

The results of a detailed epidemiological study on canine dirofilariasis in Slovakia which examined over 4,000 dogs were presented in a study Miterpáková et al. [5]. The average prevalence in individual regions ranged from 2% in northern Slovakia to more than 25% in the southwestern part of the country, with *Dirofilaria repens* being confirmed as the dominant causative agent [2]. It seems that there could be more people affected because in the absence of symptoms this infection can be overlooked. This fact is also confirmed by the recently published work describing the second case of localization of *Dirofilaria repens* within the epididymis in the presence of a pseudo-tumor in the epididymal region [3].

The presented case study represents the third case in whom *Dirofilaria repens* was confirmed in the parasitic cyst of the

epididymis. In Slovakia, the subcutaneous form predominated in terms of localization of dirofilariasis in humans. In most patients, this zoonosis causes local symptoms, which help to reveal the true nature of the disease. However, there is the possibility of latent zoonoses of this type due to the possible asymptomatic course. This is also confirmed by the high prevalence of dirofilariasis in dogs, especially in the endemic area (25%). If the patient finds a pathological mass in the area of the testicle, the further procedure in diagnosis and treatment is related to the initial examinations. Cystic formations in the testis are generally considered to be benign and which, unlike solid tumours, sometimes do not require intervention. Cystic formations in this area are often followed by the watchful waiting (WW) method. Epididymal cysts are usually painless, smooth, round structures attached to the epididymis. They are most often found in the head of the epididymis, but also in its body and tail, and can be solitary or multiple [7]. In the case of filarial origin of the parasitic cyst in any location, the symptom of a dancing fibre ('filarial dance sign') can be found during USG examination. The sign of a dancing fibre refers to the twisting movement of filariae in an enlarged cystic structure or lymphatic channels. It is identified as a hallmark of scrotal or testicular filariasis [8], or in patients who have a dilated lymphatic channels in epididymis for lead obstruction [9]. The sign of filarial dance was first described by the Brazilian radiologist Fernando Amaral and his colleagues in 1994 in a group of 14 patients infected with the *Wuchereria bancrofti* [10]. This phenomenon was later observed by other authors and is well known to sonographers [11].

If worm-like structures are found during a careful USG examination and the morphological finding during mechanical stimulation is confirmed by active movement inside the parasitic cyst, the diagnosis can be focused in this direction. In the presented case, during histopathological examination, a detailed microscopic inspection of the parasite revealed typical structures showing external notches or characteristic external longitudinal cuticular ridges, double uterus, middle intestine, longitudinal muscles and lateral chords (Fig. 2). These structures are clear evidence of the *Dirofilaria repens* worm.

We have the advantage that in the city of Košice in Slovakia there is a research institute, the Institute of Parasitology of the Slovak Academy of Sciences, which deals with parasitic zoonoses in our country. Consultation is always helpful because it prevents complications and helps to provide adequate treatment. The spread of parasites outside endemic warm areas is also made possible by environmental changes resulting from global warming, as well as population migration. Urologists may increasingly encounter cases

of unusual parasites in Central Europe that settle in the urogenital area. It is therefore beneficial to be prepared for such an eventuality [12].

CONCLUSIONS

The case report draws the attention of general practitioners, sonographers and urologists to consider dirofilariasis in the case of finding pseudo-tumours or cystic formations in the testis. Although most *Dirofilaria repens* infections have been reported in the south-western regions the presented patient came from the north-eastern part of Slovakia. However, the origin of the infection could not be proven due to the previous stay of the patient in Turkey. It is necessary to take this diagnosis into account on our territory when dealing with cases which could have occurred outside the previously known endemic areas.

REFERENCES

1. Vasilková D, Klisenbauer D, Juhás T, et al. Isolation of *Dirofilaria repens* in a vitreoretinal lesion. *Cesk Oftalmol.* 1992; 48(4): 274–80.
2. Miterpáková M, Antolová D, Ondriska F, et al. Human *Dirofilaria repens* infections diagnosed in Slovakia in the last 10 years (2007–2017). *Wien Klin Wochenschr.* 2017; 129(17–18): 634–641.
3. Boldiš V, Ondriska F, Bošák V, et al. Pseudo-Tumor of the Epididymis, a Rare Clinical Presentation of Human *Dirofilaria repens* Infection: a Report of Autochthonous Case of Dirofilariasis in Southwestern Slovakia. *Acta Parasitol.* 2020; 65(2): 550–553.
4. Miterpáková M, Ondriska F, Antolová D, et al. Epidemiológia dirofilariózy na Slovensku. *NewsLab.* 2020; 11(2): 104–105.
5. Miterpáková M, Iglodyová A, Čabanová V, et al. Canine dirofilariasis endemic in Central Europe — 10 years of epidemiological study in Slovakia. *Parasitol Res.* 2016; 115(6): 2389–95.
6. Centers for Disease Control and Prevention, 2019. Dirofilariasis. Biology. <https://www.cdc.gov/parasites/dirofilariasis/biology.html> (access: 2021.03.12).
7. Bromby A, Cresswell J. Differential diagnosis of a scrotal mass. *Trends Urol Mens Health.* 2014; 5(1): 15–18.
8. Chaubal NG, Pradhan GM, Chaubal JN, et al. Dance of live adult filarial worms is a reliable sign of scrotal filarial infection. *J Ultrasound Med.* 2003; 22(8): 765–9.
9. Adejolu M, Sidhu PS. The „filarial dance“ is not characteristic of filariasis: observations of „dancing megasperm“ on high-resolution sonography in patients from nonendemic areas mimicking the filarial dance and a proposed mechanism for this phenomenon. *J Ultrasound Med.* 2011; 30(8): 1145–50.
10. Amaral F, Dreyer G, Figueredo-Silva J, et al. Live adult worms detected by ultrasonography in human Bancroftian filariasis. *Am J Trop Med Hyg.* 1994; 50(6): 753–7.
11. Wang Z, Yang Z, Lei YY, et al. Who Is Doing the Dance in Epididymis: The Principle of Mobile Echogenicities Without Filarial Infection: Case Report. *Medicine.* 2015; 94(34): e1418.
12. Kehinde EO, Anim JT, Hira PR. Parasites of Urological Importance. *Urol Int.* 2008; 81(1): 1–13.